

THE EVOLUTION OF THE ADDUCTOR CANAL BLOCK: THE EMERGING TECHNIQUE FOR MOTOR-SPARING ANALGESIA TO THE KNEE

Jonathan P. Kline, CRNA, M.S.N.A.

KEYWORDS

adductor canal, ultrasound, saphenous nerve block

ABSTRACT

This article summarizes current relevant data regarding the adductor canal block. It provides readers with background information of this emerging technique, including history, review of literature, relevant anatomy, and the technique itself.

INTRODUCTION

The adductor canal block has recently gained attention from anesthesia and orthopedic communities. The desire to produce analgesia without the loss of motor control to the thigh seems to be beneficial. Benefits of this technique may include shorter hospital stays, earlier and more efficient rehabilitation, and pain control. Additionally, patients will retain the ability to report pain in neighboring distributions that can be involved when attempting to block the femoral nerve at the inguinal crease. This technique also embraces the emerging regional philosophy of selectivity or blocking only the area involved in the surgery. This article will review this novel technique. Review of the literature was performed using keywords *adductor canal block* and *saphenous nerve block*. Articles less than 5 years old were included, with the exception of one article which added historical context.

HISTORY

One of the earliest works leading to the development of the adductor canal block was done by van der Wal and associates in Canada.¹ In their 1993 article, they established the block's clinical viability utilizing cadavers. They described what they referred to as a "subsartorial approach" to the saphenous nerve blockade. Their intent was to describe an alternative to a traditional landmark approach to the saphenous nerve block, primarily for foot and ankle procedures. This established a foundation for clinicians to incorporate a regional blockade of the saphenous nerve to provide analgesia for surgical knee procedures.

REVIEW OF LITERATURE

Horn and colleagues made a significant step forward in 2009 in the report titled "Anatomic Basis to the Ultrasound-Guided Approach to the Saphenous Nerve Blockade."² It is arguably the earliest work establishing the sonographic description of the block. In this article, the technique describes the close proximity under ultrasound of the saphenous nerve to the descending genicular artery. They showed this technique on cadavers in 2009.

Manickam and colleagues³ were the first to link the technique of saphenous nerve blockade in the adductor canal for the purposes of knee joint analgesia. This publication described the blockade of the saphenous nerve in the adductor canal, bringing together the components in use today. These components are the placement of the probe at the mid-thigh, the ultrasound short-axis view description of the femoral artery and vein (as opposed to the descending genicular artery), the short-axis view of the sartorius, adductor longus, and magnus muscles, and the vastus medialis muscle. These findings were well-timed as Sharma et al⁴ drew the first association between femoral nerve blocks, commonly used for knee analgesia for knee surgery, and increased fall risk. This was the beginning of the push to establish a new technique that would spare the motor strength of the thigh muscles and find suitable alternatives to the femoral block which would reduce the risk of falls.

In 2011, Lund and colleagues⁵ applied the concept of performing the adductor canal block for the purposes of analgesia after major knee surgery. The investigators introduced the first peri-neural catheters to the field of adductor canal mediated analgesia and established that 30 ml of local anesthetic would effectively fill the adductor canal. The same year, Saranteas et al⁶ investigated the efficacy of needle placement under ultrasound into the adductor canal, between the sartorius muscle and the femoral artery. This work demonstrated the saphenous nerve location between the femoral artery and sartorius muscle. Of particular clinical significance was the conclusion that the saphenous nerve exits the adductor canal in over 80% of the population studied. Also in 2011, Karpoor and associates⁷ spared the undesired muscle weakness of the femoral nerve block and implemented a saphenous nerve block in the adductor canal as an effective alternative approach. They demonstrated that in over 70% of the studied cadavers, the distal portion of the femoral nerve entered the vastus medialis muscle proximal to the location of the region which contains the saphenous nerve in a location anterior to the femoral artery. This portion of the femoral nerve innervates motor control of the vastus medialis muscle.⁷ This article added further information to the relatively elusive saphenous nerve location.

In 2012, Jaeger et al⁸ conducted a proof-of-concept study which demonstrated a reduction in opioid requirement after total knee arthroplasty for study patients that received the block. Additionally in 2012, Jenstrup and colleagues⁹ sought to establish a reduction of pain during a 45-degree flexion after knee surgery, reduce morphine consumption, and formally link muscle strength preservation by means of early ambulation. They were successful in all aspects, the most notable of which was the pain reduction at the 2 and 24 hour marks.

Henningsen and some of the original Lund study investigators sought to show the incidence of saphenous nerve injury with the

ultrasound-guided adductor canal block in 2013. They demonstrated that no patients suffered saphenous nerve injury from the ultrasonography (USG) technique and over 80% of patients had successful blocks.¹⁰ This study highlighted two important aspects of the technique; it established the technique's safety and demonstrated that even under controlled conditions, it is not 100% effective. These results are consistent with other regional techniques investigation findings. In 2013, Mudumbai et al¹¹ again investigated continuous peri-neural catheters to the USG adductor canal block. Their results showed that compared with the same technique at the femoral nerve, patients ambulated farther distances postoperatively on days one and two. Their findings additionally indicated analgesia was similar between groups that received either a femoral block or an adductor canal block. Evolving the adductor canal block further as a means of preserving thigh muscle strength, Jaeger and colleagues¹² again studied the effects of the block strictly compared to femoral nerve blocks. They showed, albeit on a small study population, that, in healthy volunteers, strength was preserved to nearly a state prior to having no block at all. This study suggests that the adductor canal block does allow for thigh muscle strength preservation and may therefore reduce fall risks for patients following knee surgery.

In similar research, Kwofie et al¹³ enrolled slightly more volunteers, again studying the effect of the adductor canal block on quadriceps muscle strength and demonstrated similar results as the Jaeger study on strength preservation. Also in 2013, a head-to-head, retrospective study comparing the analgesic/ambulatory effects of the adductor canal block to femoral nerve block was published by Perlas et al¹⁴ The authors quantitatively suggested that despite the femoral nerve block showing better analgesia, the strength loss in the quadriceps muscle was approximately 50%. They also demonstrated that an adductor canal block, plus local infiltration following surgery, was associated with earlier ambulation and strength preservation. In 2013, Hanson

et al ¹⁶ illustrated that the adductor canal block with ropivacaine was superior in reducing equivalent resting pain scores than the same block with saline in patients post-arthroscopic medial meniscectomy.

Investigating the adductor canal block in other surgical procedures, Espelund et al ¹⁷ evaluated the efficacy of the block on patients post anterior cruciate ligament reconstruction in 2013. The study results failed to show any benefit of the block over intravenous (IV) non-steroidal anti-inflammatory medicines. This important study poses a question regarding the effect of the saphenous nerve innervation to this area of knee.

Another important factor which may affect block outcome is the block technique itself. Previous studies show that the saphenous nerve is located on the medial side of the distal femoral artery. However, in the Espelund study, the adductor canal block technique was approached from the lateral side of the artery. This approach required the local anesthetic to bathe the nerve from the infiltration entirely and negates the nerve's natural position. Additionally, all study blocks were performed after surgery.

Several researchers have demonstrated that regional anesthesia can inhibit the inflammatory cascade in a variety of locations.^{18,19,20,21,22} Findings suggest that regional techniques of any kind may lower pain scores more effectively when done pre-procedurally.

In 2013, Andersen et al ²³ studied the effects of an ultrasound-guided continuous peri-neural catheter technique on patients' pain scores after total knee arthroplasty. The authors concluded that pain scores were significantly reduced in the group that received ropivacaine through the adductor canal catheter versus saline. An interesting caveat, all patients in the study received a spinal anesthetic as the primary route of anesthesia, and all catheters were placed postoperatively. This study design

demonstrated two key outcomes: a reduction or elimination of the inflammatory response by implementing a regional technique prior to the generation of surgical pain and a postoperative catheter placement potentially improving block safety and efficacy. Reduction in inflammatory response effect has been demonstrated in a number of different techniques whose validity will likely have a dramatic impact on the field of regional anesthesia. Considerations for regional blockades utilizing catheter technique are that preoperative placement of catheters can be displaced by surgical manipulation or tourniquet compression to the thigh may result in catheter injury to underlying structures.

RELEVANT BLOCK ANATOMY

The relevant anatomy for the adductor canal block focuses on the specific target of the saphenous nerve. The femoral nerve originates from the L-2 to L-4 spinal nerves. These L-2 through L-4 nerves join together as a structure known as the lumbar plexus. This plexus passes through the psoas compartment made of the psoas muscle posteriorly and the quadratus lumborum anteriorly. The femoral nerve emerges from under the inguinal canal and bifurcates into two smaller peripheral nerves in the anterior thigh.²⁴ Near the location of the superior third of the thigh, the femoral nerve continues its path deep into the leg to innervate the rectus femoris, vastus lateralis, vastus medialis, vastus intermedius, and sartorius. This group is primarily responsible for extending the lower leg and lifting the thigh forward and transferring weight during ambulation. The femoral nerve also sends off a pure sensory nerve called the saphenous nerve in the anterior thigh. The saphenous nerve separates from the femoral nerve and continues its path toward the knee accompanying the femoral artery and vein. This trio travels through the adductor canal. This canal is made up of the sartorius muscle superficially, and the vastus intermedius muscle as the deep component. The side wall completing a triangle is the adductor longus (see Figure 1). Within these three structures, a tunnel or canal is formed, allowing for passage of the saphenous nerve

and the distal femoral artery and vein. The saphenous nerve is responsible for the sensory innervation of the anterior knee. It sends a sensory branch inferiorly to the region under the patella called the infrapatellar nerve. With this information, it seems logical that by blocking only the saphenous nerve, it is possible to cause analgesia to the anterior knee while preserving the anterior thigh motor control.

TECHNIQUE

There are a few techniques described for blocking the saphenous nerve selectively. Advancing a needle blindly into the adductor canal was the first landmark-based technique, using the middle third of the inner thigh as the starting point. Today, with the advances of ultrasound guidance, this is not recommended. The adductor canal's relevant structures can be easily viewed with ultrasound.



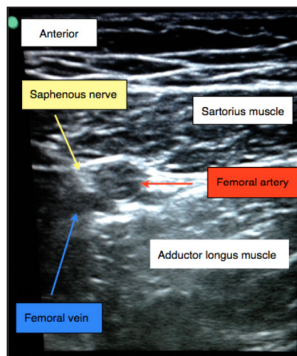
Video: Adductor Canal Ultrasound

Begin by slightly externally rotating the thigh. Select a linear probe, and set the depth to around 4 cm. Begin the scan by placing the probe in the midpoint of the patella and inguinal crease, on the medial side of the thigh. The probe should be positioned to allow for a short-axis view of the distal femoral artery. If in doubt of the artery's identity, track the femoral artery path starting at the inguinal crease as in a femoral block or femoral vessel cannulation. Once satisfied with the artery's identity, place the adductor canal in view, with distal femoral artery in short-axis visible. The Doppler modes can be used to confirm the structures' pulsatile flow. The sartorius and adductor longus should be easily visible (see Figure 1).

Prep the needle insertion region with the institution's antiseptic solution. For awake patients, advance a small gauge needle in plane through the projected needle path and deposit a fast-acting local anesthetic solution such as lidocaine or mepivacaine. Once the needle path has been localized, advance a long blunt block

needle under the artery. It is unlikely that the saphenous nerve will be visible but tilting the probe about 20-30 degrees away from the head can help. Once the needle has arrived deep to the artery, aspirate and begin to deposit the local anesthetic block solution. Redirect the needle in plane as necessary to fill the adductor canal. This volume will vary depending on a variety of factors, but one study showed that 30ml can fill the canal.⁵

Figure 1. The Relevant Structures Within the Adductor Canal



SUMMARY

The adductor canal block is in its infancy compared to other well-established regional techniques. In 2013, the greatest number of research articles on various aspects of the block was published. Unlike other traditional techniques that seek to cause a sensory as well as a motor blockade, the adductor canal block attempts to spare the motor block of the neighboring distributions in an attempt to offer selective analgesia and strength preservation. A frequently asked question is “Can the nerve stimulator be used as a secondary identifier for the saphenous nerve, either in combination or solo for saphenous nerve localization?” The answer seems to be that it can.

Although the saphenous nerve is a purely sensory nerve, the nerve stimulator is not without merit. However, sensory nerves do not elicit a motor twitch, so how then can this be explained? This is because although they have a higher rheobase[†] and

[†] In this text, the rheobase is a physics term²⁶ that describes the lowest electrical intensity required to elicit a nerve impulse.

chronaxie[‡], they will elicit an appreciable response in awake patients. Clinical electrical current settings for traditional motor twitch elicitation are between 0.2-1.0 mA. This avoids undesired sensory responses traditionally associated with stimulator settings above 1.0. These increased current settings above 1.0 mA produce sensory pulsations. These can be useful for sensory nerve localization.²⁵ It should be noted that as current settings exceed 1.0 mA, there is an increased likelihood that the patient will complain of painful nerve pulsations. Consequently, combining the nerve stimulator with ultrasound for nerve identity seems of some use, although not one study included in this article employed this technique.

The majority of the recent studies^{2-5, 17} are optimistic that this relatively novel technique shows promise to accomplish the goal of knee analgesia and thigh strength preservation. Although it is too early to be certain of its success, many of the various aspects regarding this technique have been cursorily reviewed. The research currently available is overwhelmingly positive, with only one reviewed study which did not demonstrate adductor canal block benefit over IV medications following knee arthroscopy. Current understanding regarding the evolution of the adductor canal block, while limited, shows promise for this emerging technique to potentially address the issue of surgical knee pain analgesia and preservation of upper leg motor strength.

AUTHOR INFO

Jonathan P. Kline, CRNA, M.S.N.A.

Director of Education

Twin Oaks Anesthesia Services, LLC

26714 Winged Elm Drive, Wesley Chapel, Florida 33544

813-857-5559 / nerveblocker@gmail.com

[‡] In this text, the chronaxie is a physics term describing the time needed that, doubling the rheobase, will elicit the same impulse.²⁶

REFERENCES

- 1 van der Wal M, Lang SA, Yip RW. Transsartorial approach for saphenous nerve block. *Can J Anaesth*. 1993;40(6):542-546.
- 2 Horn J, Pitsch T, Salinas F, et al. Anatomic basis to the ultrasound-guided approach for saphenous nerve blockade. *Reg Anesth Pain Med*. 2009;34(5):486-489.
- 3 Manickam B, Perlas A, Duggan E, et al. Feasibility and efficacy of ultrasound-guided block of the saphenous nerve in the adductor canal. *Reg Anesth Pain Med*. 2009;34(6):578-580.
- 4 Sharma S, Iorio R, Specht L, et al. Complications of femoral nerve block for total knee arthroplasty. *Clin Orthop Relat Res*. 2010;468(1):135-140. Published online August 13, 2009. doi: PMCID: PMC2795813.
- 5 Lund J, Jenstrup T, Jaeger P, et al. Continuous adductor-canal-blockade for adjuvant post-operative analgesia after major knee surgery: preliminary results. *Acta Anaesthesiol Scand*. 2011;55:14-19.
- 6 Saranteas T, Anagnostis G, Paraskeuopoulos T, et al. Anatomy and clinical implications of the ultrasound-guided subsartorial saphenous nerve block. *Reg Anesth Pain Med*. 2011;36(4):399-402.
- 7 Karpoor R, Adhikary D, Siefring C, et al. The saphenous nerve and its relationship to the nerve to the vastus medialis in and around the adductor canal: an anatomical study. *Acta Anaesthesiol Scand*. 2012;56(3):365-367.
- 8 Jaeger P, Grevstad M, Henningsen B, et al. Effect of adductor-canal-blockade on established, severe post-operative pain after total knee arthroplasty: a randomized study. *Acta Anaesthesiol Scand*. 2012;56(8):1013-1019.
- 9 Jenstrup MT, Jaeger P, Lund J, et al. Effects of adductor-canal-blockade on pain and ambulation after total knee arthroplasty: a randomized study. *Acta Anaesthesiol Scand*. 2012;56(3):357-64.

- 10 Henningsen MH, Jaeger P, Hilsted KL, et al. Prevalence of saphenous nerve injury after adductor-canal-blockade in patients receiving total knee arthroplasty. *Acta Anaesthesiol Scand*. 2013;57(1):112-117.
- 11 Mudumbai SC, Kim TE, Howard SK, et al. Continuous adductor canal blocks are superior to continuous femoral nerve blocks in promoting early ambulation after TKA. *Clin Orthop Relat Res*. 2013. Published Online July 2013. http://www.clinorthop.org/Journals/Online_First.html. Last accessed Nov 2013
- 12 Jaeger P, Neilsen Z, Henningsen MH, et al. Adductor canal block versus femoral nerve block and quadriceps strength: a randomized, double-blind, placebo-controlled, crossover study in healthy volunteers. *Anesthesiology*. 2013;118(2):409-415.
- 13 Kwofie M, Shastri U, Gadsden J, et al. The effects of ultrasound-guided adductor canal block versus femoral nerve block on quadriceps strength and fall risk: a blinded, randomized trial of volunteers. *Reg Anesth Pain Med*. 2013;38(4):321-325.
- 14 Perlas A, Kirkham K, Billing R, et al. The impact of analgesic modality on early ambulation following total knee arthroplasty. *Reg Anesth Pain Med*. 2013;38(4):334-339.
- 15 Ilfield B, Hadzic A. Walking the tightrope after knee surgery: optimizing postoperative analgesia while minimizing quadriceps weakness. *Anesthesiology*. 2013;118(2):248-250.
- 16 Hanson N, Derby R, Auyong DB, et al. Ultrasound-guided adductor canal block for arthroscopic medial meniscectomy: a randomized, double-blind trial. *Can J Anaesth*. 2013;60(9):874-880.
- 17 Espelund M, Fomsgaard J, Haraszuk J, et al. Analgesic efficacy of ultrasound-guided adductor canal blockade after arthroscopic anterior cruciate ligament reconstruction: a randomised controlled trial. *Eur J Anaesthesiol*. 2013;30(7):422-428.

- 18 Beilin B, Bessler H, Mayburd E, et al. Effects of preemptive analgesia on pain and cytokine production in the postoperative period. *Anesthesiology*. 2003;98:151-155.
- 19 Freise H, Daudel F, Grosserichter C, et al. Thoracic epidural anesthesia reverses sepsis-induced hepatic hyperperfusion and reduces leukocyte adhesion in septic rats. *Crit Care*. 2009;13:R116.
- 20 Le Bars D, Adam F. Nociceptors and mediators in acute inflammatory pain. *Ann Fr Anesth Reanim*. 2002;21:315-335.
- 21 Sheeran P, Hall GM. Cytokines in anaesthesia. *Br J Anaesth*. 1997;78:201-219.
- 22 Watkins LR, Maier SF, Goehler LE. Immune activation: the role of pro-inflammatory cytokines in inflammation, illness responses and pathological pain states. *Pain*. 1995;63:289-302.
- 23 Andersen H, Gyrn J, Moller L, et al. Continuous saphenous nerve block as supplement to single-dose local infiltration analgesia for postoperative pain management after total knee arthroplasty. *Reg Anesth Pain Med*. 2013;38(2):106-111.
- 24 Hadzic, A. Chapter 35. In: *Textbook of Regional Anesthesia and Acute Pain Management*. New York, NY: McGraw Hill;2007:500.
- 25 Hadzic, A. Chapter 5. In: *Textbook of Regional Anesthesia and Acute Pain Management*. New York, NY: McGraw Hill;2007:94-98.
- 26 Hadzic, A. Chapter 5. In: *Textbook of Regional Anesthesia and Acute Pain Management*. New York, NY: McGraw Hill;2007:94-95.